



A Survey on Medical Diagnosis of Retinopathy and Detection Techniques

Aishwarya Ajit Padwalkar¹, Assistant Professor Dr. G. V. Khandekar²,
Assistant Professor Upendra Singh³, Diksha Rawat⁴

Sandvik- Ireland¹

2Department of Applied Sciences & Engineering

SKN Sinhgad Institute of Technology & Science, Lonavala, Pune, India²

Department of Information Technology

Shri G.S. Institute of Technology and Science, Indore, India³

JPMorganChase, USA⁴

Abstract- Diabetic Retinopathy is a frequent complication of diabetes mellitus that leads to retinal lesions affecting vision. Without timely detection, it can result in permanent blindness. Sadly, Diabetic Retinopathy is irreversible, and medical interventions only help preserve existing vision. Early identification and treatment of DR play a crucial role in minimizing the risk of vision impairment. However, manual diagnosis of retinal fundus images by ophthalmologists is time-consuming, labor-intensive, costly, and susceptible to errors, unlike automated computer-aided diagnostic systems. This paper has summarized the type of retinopathy and various stages before getting blindness. Many of researcher proposed models that find the disease in early stages by analyzing medical images. Various techniques of image optimization, analysis and classification were discussed. Paper has summarized the image features that were used in different research article for identify the retinopathy image class.

Keywords— Medical image diagnosis, Frequency Feature, Clustering, DIP.

I. INTRODUCTION

Early diagnosis significantly enhances the effectiveness of treatment in the medical field. Diabetes mellitus, a metabolic disorder characterized by elevated blood glucose levels due to insulin deficiency or resistance, currently affects approximately 425 million adults globally [1], [2]. The condition can lead to complications in various organs, including the retina, heart, kidneys, and nervous system [1], [2].

One of the most serious ocular complications of diabetes is Diabetic Retinopathy (DR), a progressive disease that results in the swelling and leakage of blood vessels in the retina [3]. If not diagnosed and managed in time, DR can advance to a stage where it severely impairs vision or causes irreversible blindness. It is responsible for about 2.6% of global blindness cases [4]. The risk of developing DR increases with the duration of diabetes, making regular retinal examinations critical for early



identification and timely intervention [5]. DR is commonly diagnosed through the detection of retinal lesions such as microaneurysms (MA), hemorrhages (HM), and soft and hard exudates (EX) in fundus images [1].

To address the limitations of manual screening methods, automated detection systems are being increasingly explored. Manual evaluation of retinal fundus images by ophthalmologists is not only time-consuming and labor-intensive but also prone to human error and subjectivity. This has led to a growing interest in automated solutions that leverage image processing and machine learning techniques for reliable and scalable DR detection [6].

Machine learning offers a powerful approach to automate the screening process for DR. For instance, Sambyal et al. [7] proposed a diagnostic model that utilizes two machine learning classifiers: Optimum-Path Forest (OPF) and Restricted Boltzmann Machine (RBM). These classifiers were evaluated using metrics such as accuracy, specificity, and sensitivity, demonstrating their potential in retinal image classification.

In parallel, deep learning has emerged as a crucial tool for analyzing complex medical images. Khan et al. [8] developed a computational method that applies the Xception deep learning architecture combined with a dense neural network to classify ocular scans as either DR-positive or DR-negative. Such methods offer high accuracy and consistency, making them promising alternatives to traditional screening techniques for early DR detection and monitoring.

Type of Retinopathy

Retinopathy is a medical condition primarily affecting the retina and its network of blood capillaries, often triggered by diabetes. The blood vessels in the retina exhibit a tree-like branching structure with gentle curves, originating from a central region known as the optic disc. This optic disc, a bright yellowish area with a diameter of approximately 1.5 to 2 mm, serves as the point where arteries and optic nerve fibers emerge. It acts as a conduit for transmitting electrical signals from the retina to the brain's visual cortex. The average diameter of these retinal vessels is about 1/40th of the entire retina [9].

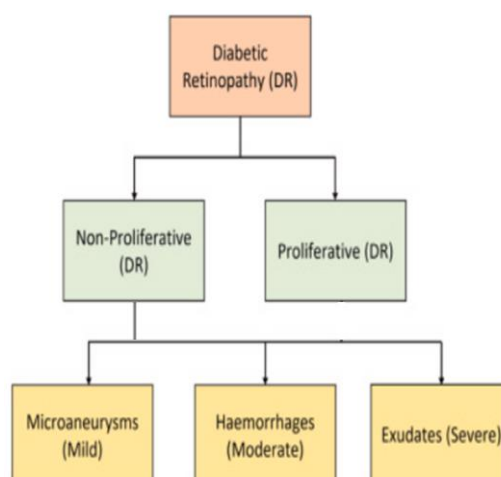


Fig. 1 shows the stages of DR.



Diabetic Retinopathy (DR) is a complex and progressive complication of diabetes that can lead to significant visual impairment or even blindness if not diagnosed and managed promptly [10]. DR is generally classified into two main types: Non-Proliferative Diabetic Retinopathy (NPDR) and Proliferative Diabetic Retinopathy (PDR). Proliferative DR can be further sub-divided into categories based on the nature of retinal damage, including microaneurysms, hemorrhages, and exudates [11].

These classifications and disease progression stages are visually represented in Figure 1, while Non-Proliferative DR (NPDR): This is the early stage of DR, characterized by the presence of retinal edema and hard exudates. It usually begins without noticeable symptoms but can progress if untreated.

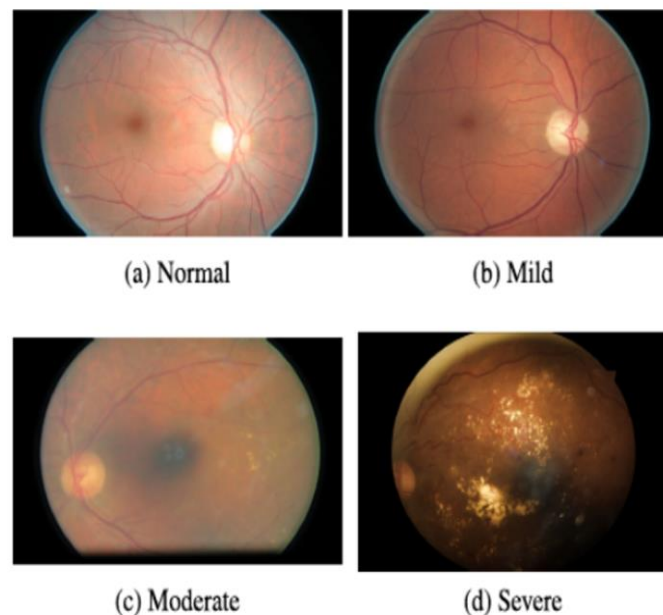


Fig. 2 illustrates the different lesions associated with DR.

Proliferative DR (PDR): This is the more advanced form of the disease, marked by the growth of abnormal new blood vessels on the retina, a process known as neovascularization. These vessels are fragile and prone to leaking, often resulting in vitreous hemorrhages and severe vision loss.

Hemorrhages: These are considered significant indicators of disease progression. They appear as irregular dark patches on the retina and may be categorized into superficial and deep retinal hemorrhages.

Exudates: These are yellowish-white or reddish-yellow deposits, often round or oval in shape, that accumulate due to fluid leakage from damaged retinal vessels. They are a key clinical marker in DR diagnosis.

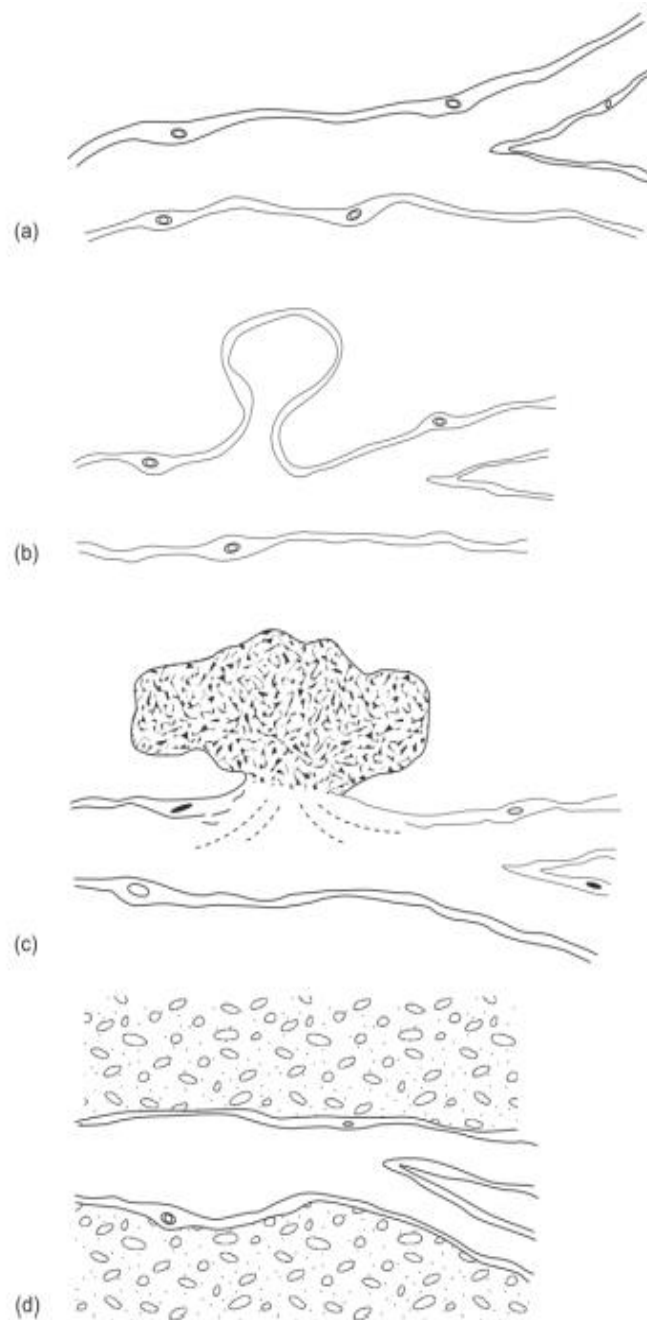


Fig. 3 Representations of various types of damage to capillaries in DR. (a) normal capillary. (b) microaneurysm. (c) hemorrhage. (d) exudate [5].

Microaneurysms: Recognized as one of the earliest signs of proliferative DR, microaneurysms appear as small red dots on the retinal surface. If not detected and treated early, they can rupture and leak, contributing to retinal dysfunction and visual degradation.

As shown in Figure 3, different complications may arise at various stages of DR, including:

Microaneurysms: Detected in mild to proliferative stages.



Hemorrhages: Seen in moderate to proliferative stages.

Exudates: Appear in moderate to severe and proliferative stages.

Cotton-wool spots: Typically occur during severe, pre-proliferative, and proliferative stages.

Intraretinal Microvascular Abnormalities (IRMA): Commonly observed in the proliferative stage [5].

II. RELATED WORK

Qureshi et al. [12] introduced an innovative model, which incorporates an active learning strategy based on the expected gradient length. This technique intelligently selects the most informative image patches to identify subtle retinal patterns. The model operates through a two-phase process that facilitates both prediction and annotation of retinal images, effectively supporting the grading of diabetic retinopathy severity. When evaluated on the EyePACS dataset, model demonstrated exceptional performance, achieving sensitivity of above 90%.

Bashir et al. [13] compiled a diverse dataset named "DR-Insight" by collecting digital fundus images from prominent eye hospitals in Pakistan and established online sources. They proposed a deep learning framework called the Residual-Dense System for Diabetic Retinopathy, which integrates residual and dense blocks along with a transition layer. This architecture enhances feature extraction and classification capability, making it suitable for DR assessment.

Amalia et al. [14] presented a hybrid deep learning method that combines Convolutional Neural Networks with Long Short-Term Memory networks for detecting diabetic retinopathy from retinal fundus images. Features were extracted using the GoogleNet CNN architecture and subsequently translated into descriptive sequences using LSTM. This approach achieved a notable classification accuracy of 90%. The model's descriptive outputs serve as diagnostic support for radiologists, offering a novel direction for enhancing interpretability in clinical practice.

Daanouni et al. [15] explored the robustness of the MobileNet CNN model against adversarial attacks generated using the Fast Gradient Sign Method. To mitigate such vulnerabilities, they proposed a model named NSL-MHA-CNN, which incorporates Neural Structure Learning and a Multi-Head Attention mechanism. This approach enables robust training with adversarial examples while preserving model performance and maintaining training efficiency. The study offered both theoretical and empirical insights into the model's stability under adversarial conditions.

Jagadesh et al. [16] proposed a two-stage strategy for automatic diabetic retinopathy classification. Addressing the imbalance in positive cases, they enhanced the detection of Optical Discs and Blood Vessels using a refined contoured convolutional transformer known as IC2T. The model includes a dual transformer block that captures both local and global contexts for reliable detection. In the second phase, an Improved Coordination Attention Mechanism is employed to identify key retinal biomarkers such as microaneurysms, hemorrhages, and exudates.

Tavakoli et al. [17] developed a hybrid approach combining supervised and unsupervised methods to enhance the detection of microaneurysms. Initially, retinal images undergo preprocessing to eliminate background variations. Key anatomical structures like the optic nerve head and retinal vessels are then detected using the Radon Transform and masked using overlapping window techniques. Finally, a



combination of Random transform and a supervised Support Vector Machine is applied to identify and count MAs.

Yi et al. [18] proposed a novel encoder-decoder network for efficient segmentation of microvascular lesions. The encoder was designed to be lightweight and scalable in terms of depth, width, and resolution to enhance training speed. An attention mechanism was integrated in the decoder phase using Concurrent Spatial and Channel Squeeze and Channel Excitation blocks to maximize spatial and channel-wise information utilization. Additionally, a compound loss function and transfer learning were used to address class imbalance and improve segmentation accuracy.

III. IMAGE FEATURES FOR CLASSIFICATION

Color Feature: Retinopathy image analysis relies heavily on color information, as the image itself is a matrix of pixel values, where each pixel encodes a specific color based on the selected image format RGB, shown in fig. 4. Color features are critical for distinguishing various regions within the retina, such as blood vessels, optic disc, and lesions. These features are widely used in tasks like image re-ranking, classification, and object detection. In retinal images, color variations can help in identifying abnormalities such as hemorrhages, micro aneurysms, and exudates. An example of color-based feature representation, especially using the HSV color model, is shown in Fig. 5, where hue, saturation, and value components highlight different structures within the retina.

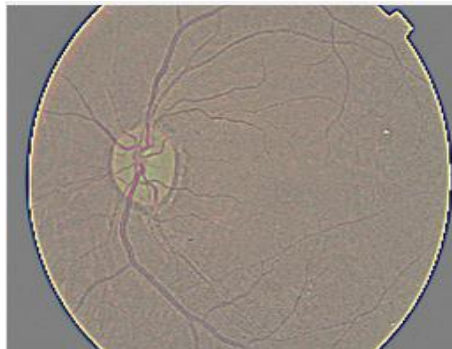


Fig. 4 Retina color feature image.

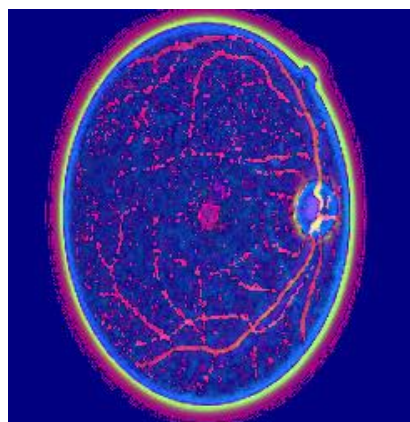


Fig. 5 Retina HSV feature of an image.



Active Contour: Active contour models, also known as snakes, are used to detect object boundaries within images through iterative deformation. This method is particularly effective in segmenting complex anatomical structures like the optic disc or pathological regions in the retina. The contour evolves over time under the influence of internal and external forces until it aligns with the true boundary of the object. In the context of retinopathy images, active contour techniques help to delineate regions of interest, such as lesions or abnormal tissue growth, based on intensity and spatial continuity. The feature extracted using this approach enhances the structural representation of the retina, as illustrated in Fig. 6, which demonstrates an active contour-based retinal image feature.



Fig. 6 Retina active contour based image feature.




Fig. 7 Retina DCT based image feature.

Discrete Cosine Transform (DCT): The Discrete Cosine Transform (DCT) is widely used in image processing for feature extraction, particularly in the frequency domain. It converts the image into a sum of cosine functions at various frequencies, allowing for compact representation of image



information. In retinopathy image analysis, DCT helps in reducing dimensionality while preserving essential texture and contrast features. It effectively captures variations in retinal regions that may indicate disease progression. Fig. 7 also shows the application of DCT on retinal images, where frequency-based patterns highlight critical features for classification or diagnosis.

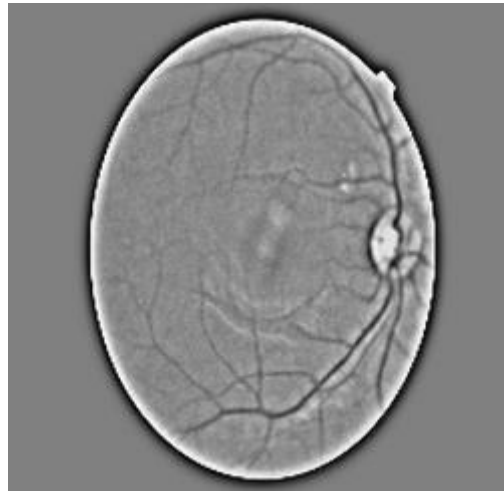

Fig. 8 Retina edge feature of an image.

Edge Feature Edge detection is fundamental in identifying boundaries and structural transitions in retinal images. Objects in an image are defined not only by their color or texture but also by the lines or transitions that mark their limits—these are known as edges. Detecting these edges is crucial for outlining anatomical features such as blood vessels or lesions. Grayscale images are commonly used in edge detection processes to simplify the analysis. Several edge detection algorithms exist, such as the Sobel, Prewitt, and Canny operators. Among them, the Canny edge detection algorithm is preferred due to its accuracy and ability to detect sharp, well-defined edges. This feature plays a significant role in highlighting boundaries in retinal images, as depicted in Fig. 1.3, which demonstrates edge detection in a retinopathy image using the Canny algorithm.

IV. TECHNIQUES OF IMAGE DIAGNOSIS

Supervised Learning: Supervised learning is one of the most widely used paradigms in machine learning, particularly in medical image analysis. In this approach, models are trained on a labeled dataset, where the input features are paired with the correct output labels. The goal is to learn a mapping function that can generalize to unseen data and accurately predict outcomes for new instances. This approach has proven effective in classifying retinal images for Diabetic Retinopathy detection, as it enables the system to learn from expert-annotated datasets and apply learned patterns to diagnose new cases [19], [20].

Unsupervised Learning: Unsupervised learning techniques, in contrast, operate on unlabeled datasets. These algorithms aim to discover hidden patterns or groupings in the data by modeling the underlying structure or distribution, often represented as $P(X)$, where X denotes the input data. This approach is particularly useful in clustering or anomaly detection tasks within large-scale medical



datasets, where manual annotation is not feasible. In DR research, unsupervised methods are used to segment retinal structures and identify lesions without prior labeling [21].

Reinforcement Learning: Reinforcement learning (RL) introduces a goal-driven framework where agents learn optimal behaviors through interactions with an environment. The agent receives rewards or penalties based on its actions, leading it to maximize long-term rewards. RL has recently been explored in medical imaging tasks such as adaptive image enhancement or sequential diagnosis planning, where the system continuously improves by learning from feedback [22].

Support Vector Machines (SVM): Support Vector Machines are supervised classifiers that aim to find the hyperplane that maximally separates classes in a high-dimensional space. Unlike linear regression, SVMs use a hinge loss function and can be extended to non-linear problems via kernel functions (e.g., radial basis function, polynomial). SVMs are particularly suited for binary classification problems and have been effectively applied to DR classification due to their robustness in high-dimensional feature spaces [23].

Probabilistic Graphical Models (PGMs): PGMs, such as Bayesian Networks and Markov Random Fields, model the conditional dependencies among variables using graph structures. These models leverage probabilistic inference to make predictions, which is especially useful in medical domains where uncertainty is inherent. In the context of DR, PGMs help in modeling complex relationships among various retinal features and disease stages [24].

Decision Tree-Based Models: Decision trees are hierarchical models that split data into branches based on feature thresholds, ultimately leading to a prediction at the leaf nodes. Advanced ensemble versions, such as Random Forests and Gradient Boosting Machines, combine multiple weak learners to form a strong predictive model. These models are widely used for medical diagnosis due to their interpretability and high accuracy. In DR detection, they are employed to evaluate multiple image features such as color, texture, and shape in a hierarchical manner [25].

V. CONCLUSION

Diabetic Retinopathy (DR) is a critical diabetes-related complication that can lead to irreversible vision loss if not detected early. This paper highlighted the stages of DR and surveyed various machine learning and deep learning-based approaches for its early detection using retinal images. By analyzing features such as color, edges, contours, and frequency components, automated systems can enhance diagnostic accuracy. These intelligent techniques significantly reduce the burden on ophthalmologists and enable scalable, efficient, and cost-effective screening for preventing blindness in diabetic patients. It was found that use of learning model for retinopathy detection is improved by feature optimization. In future scholars can proposed a multiclass retinopathy detection model with low execution time.



REFERENCES

1. R. Taylor, D. Batey. "Handbook of retinal screening in diabetes: diagnosis and management (second ed.)", John Wiley & Sons, Ltd Wiley-Blackwell (2012).
2. International diabetes federation - what is diabetes. <https://www.idf.org/aboutdiabetes/what-is-diabetes.html>.
3. American academy of ophthalmology-what is diabetic retinopathy? <https://www.aao.org/eye-health/diseases/what-is-diabetic-retinopathy>
4. [4] R.R. Bourne, et al. Causes of vision loss worldwide, 1990-2010: a systematic analysis *Lancet Global Health*, 1 (6) (2013), pp. 339-349
5. [5] C.A. Harper, J.E. Keeffe Diabetic retinopathy management guidelines *Expert Rev Ophthalmol*, 7 (5) (2012), pp. 417-439.
6. Zhu C.Z., Hu R., Zou B.J., Zhao R.C., Chen C.L., Xiao Y.L. Automatic Diabetic Retinopathy Screening via Cascaded Framework Based on Image- and Lesion-Level Features Fusion. *J. Comput. Sci. Technol.* 2019 346. 2019;34:1307-1318.
7. Sambyal N., Saini P., Syal R., Gupta V. Modified Residual Networks for Severity Stage Classification of Diabetic Retinopathy. *Evol. Syst.* 2022:1-19. doi: 10.1007/s12530-022-09427-3.
8. Khan A.I., Kshirsagar P.R., Manoharan H., Alsolami F., Almalawi A., Abushark Y.B., Alam M., Chamato F.A. Computational Approach for Detection of Diabetes from Ocular Scans. *Comput. Intell. Neurosci.* 2022
9. Ali, S., Li, J., Pei, Y., Khurram, R., Rehman, K.U., Mahmood, T.: A comprehensive survey on brain tumor diagnosis using deep learning and emerging hybrid techniques with multi-modal mr image. *Arch. Comput. Methods Eng.* 29(7), 4871-4896 (2022).
10. Kaur, J.; Mittal, D. A generalized method for the detection of vascular structure in pathological retinal images. *Biocybern. Biomed. Eng.* 2017, 37, 184-200.
11. Koetting, C. The Four Stages of Diabetic Retinopathy; *Modern Optometry*: Fairfax, VA, USA, 2019; pp. 21-24.
12. Qureshi, I.; Ma, J.; Abbas, Q. Diabetic retinopathy detection and stage classification in eye fundus images using active deep learning. *Multimed. Tools Appl.* 2021, 80, 11691-11721.
13. Bashir, I.; Sajid, M.Z.; Kalsoom, R.; Ali Khan, N.; Qureshi, I.; Abbas, F.; Abbas, Q. RDS-DR: An Improved Deep Learning Model for Classifying Severity Levels of Diabetic Retinopathy. *Diagnostics* 2023.
14. R Amalia, ABustamam, and D Sarwinda. Detection and description generation of diabetic retinopathy using convolutional neural network and long short-term memory. *Journal of Physics: Conference Series*, 1722(1):012010, January 2021.
15. O. Daanouni, B. Cherradi and A. Tmiri, "NSL-MHA-CNN: A Novel CNN Architecture for Robust Diabetic Retinopathy Prediction Against Adversarial Attacks," in *IEEE Access*, vol. 10, pp. 103987-103999, 2022.
16. B. N. Jagadesh, M. G. Karthik, D. Siri, S. K. K. Shareef, S. V. Mantena and R. Vatambeti, "Segmentation Using the IC2T Model and Classification of Diabetic Retinopathy Using the Rock Hyrax Swarm-Based Coordination Attention Mechanism," in *IEEE Access*, vol. 11, pp. 124441-124458, 2023.
17. M. Tavakoli, A. Mehdizadeh, A. Aghayan, R. P. Shahri, T. Ellis and J. Dehmeshki, "Automated Microaneurysms Detection in Retinal Images Using Radon Transform and Supervised Learning:



- Application to Mass Screening of Diabetic Retinopathy," in IEEE Access, vol. 9, pp. 67302-67314, 2021.
18. D. Yi, P. Baltov, Y. Hua, S. Philip and P. K. Sharma, "Compound Scaling Encoder-Decoder (CoSED) Network for Diabetic Retinopathy Related Bio-Marker Detection," in IEEE Journal of Biomedical and Health Informatics, vol. 28, no. 4, pp. 1959-1970, April 2024.
 19. Kaur, T., & Gandhi, T. K. (2020). Automated diabetic retinopathy detection using image processing and machine learning. *Procedia Computer Science*, 167, 719–726.
 20. Gulshan, V., et al. (2016). Development and validation of a deep learning algorithm for detection of diabetic retinopathy in retinal fundus photographs. *JAMA*, 316(22), 2402–2410.
 21. Almazroi, A. A., et al. (2018). Retinal image segmentation using unsupervised clustering methods: A review. *Computer Methods and Programs in Biomedicine*, 163, 1–14.
 22. Yu, F., et al. (2019). Reinforcement learning in medical image analysis: A review. *Journal of Imaging*, 5(4), 39.
 23. Rasti, R., Rabbani, H., & Mehridehnavi, A. (2017). Macular OCT classification using a multi-scale convolutional neural network ensemble. *IEEE Transactions on Medical Imaging*, 37(4), 1026–1035.
 24. Murphy, K. P. (2012). *Machine learning: A probabilistic perspective*. MIT press.
 25. Chen, T., & Guestrin, C. (2016). XGBoost: A scalable tree boosting system. In *Proceedings of the 22nd ACM SIGKDD international conference on knowledge discovery and data mining* (pp. 785–794).